

# Esthetic Indexes in Implant-Supported Fixed Prosthesis: A Survey Study

## *İmplant Destekli Sabit Protezlerde Estetik İndeksler: Bir Anket Çalışması*

 **Hamiyet Güngör Erdoğan,**  **Ceren Elif Kendirli**

Department of Prosthodontics, Lokman Hekim University Faculty of Dentistry, Ankara, Türkiye

### Abstract

**Introduction:** To evaluate two patients with implant-supported single-tooth restorations in the maxillary anterior region using the pink esthetic score/white esthetic score (PES/WES) and Copenhagen index score (CIS).

**Methods:** A questionnaire study was conducted at the Lokman Hekim University Faculty of Dentistry to evaluate two different photographs of patients with a single implant restoration in the anterior region and a natural tooth symmetrical to this restoration. Forty-five 4<sup>th</sup> and 5<sup>th</sup> year students participated in the evaluation. The questionnaire asked for the scores of PES/WES and CIS. The scores for PES/WES were 0 for significantly different, 1 for slightly different, and 2 for no difference; for CIS, the scores were 1 for excellent, 2 for satisfactory, 3 for moderate, and 4 for poor similarity. The student scores for each esthetic index were calculated as percentages (%). The study was conducted in accordance with the Declaration of Helsinki.

**Results:** The PES/WES score 0 values for Case 1 was as follows: mesial papilla 21.1%, distal papilla 26.3%, crown form 18.4%, and crown surface structure 18.4%; whereas for Case 2, mesial papilla was 11.1%, distal papilla 15.6%, crown form 26.7%, and crown surface structure 11.1%. The CIS score 4 values for Case 1 was as follows: crown morphology 0%, symmetry/harmony 2.6%, mesial papilla 5.3%, and distal papilla 5.3%; whereas for Case 2, crown morphology was 9.3%, symmetry/harmony 7%, mesial papilla 4.7%, and distal papilla 4.7%.

**Discussion and Conclusion:** The CIS provided more options, and the percentage distribution of the results was closer to each other. The CIS was found to be more applicable in the esthetic evaluation of restorations.

**Keywords:** Copenhagen Index Score (CIS); Esthetic Indices; Pink Esthetics Index/White Esthetic Index (PES/WES)

Patients' expectations in dental implantology are usually the restoration of lost functions and esthetics. The esthetic and functional success of implant treatment are closely related to the surrounding hard and soft tissues. Many

criteria need to be evaluated to provide optimum esthetics in the anterior region of implant-supported prostheses.<sup>[1]</sup>

Proper preoperative planning is critical for providing an ideal esthetic to the final permanent prosthesis. While

The article was presented as an oral presentation at the 27<sup>th</sup> International Dental Congress of the Turkish Dental Association on Saturday, October 28, 2023.

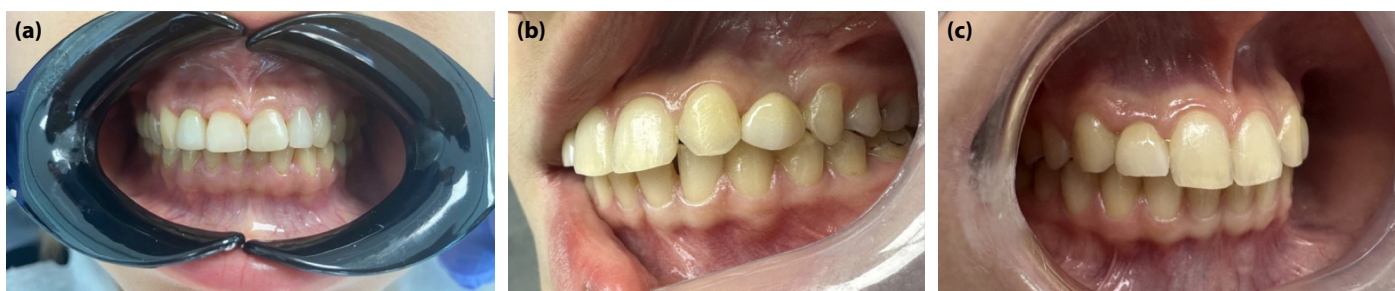**Cite this article as:** Güngör Erdoğan H, Kendirli CE. Esthetic Indexes in Implant-Supported Fixed Prosthesis: A Survey Study. Lokman Hekim Health Sci 2024;4(3):151–156.

**Correspondence:** Ceren Elif Kendirli, M.D. Lokman Hekim Üniversitesi, Diş Hekimliği Fakültesi, Protetik Diş Tedavisi Anabilim Dalı, Ankara, Türkiye

**E-mail:** cerenkendirli@gmail.com **Submitted:** 09.07.2024 **Revised:** 08.08.2024 **Accepted:** 01.11.2024

**OPEN ACCESS** This is an open access article under the CC BY-NC license (<http://creativecommons.org/licenses/by-nc/4.0/>).





**Figure 1.** (a) Case 1: Intraoral anterior view; (b) Case 2: Left lateral view; (c) Case 2: Right lateral view.

evaluating the planned prosthetic restoration, the position of the implant, the emergence profile and structure of the gingival tissue, and the anatomical form of the alveolar bone should be taken into consideration, along with the adjacent teeth, lips, and gingiva.<sup>[2]</sup> When treating a single missing tooth in the anterior region with implants, the aim is to achieve ideal symmetry; however, despite all planning procedures, ideal esthetics may not be achieved. The prosthetic material used, the depth and angle of the implant in the bone, the phenotype of the gingiva in the region, the presence of ideal soft tissue, and the cause of tooth loss are important for an ideal crown.<sup>[2,3]</sup>

In the literature, some parameters affecting esthetics for implant-supported restorations have been scored, and esthetic indices have been found to provide a treatment plan in accordance with expectations.<sup>[4]</sup> The use of these indices is important for the esthetic standardization of restorations between physicians. In implantology, the indices used to evaluate esthetics to objectify the esthetic perception that may differ between individuals and make comparisons are as follows: papilla score, pink esthetic score (PES), pink esthetic score/white esthetic score (PES/WES), implant crown esthetic index (ICEI), implant restoration esthetic index (IREI), peri-implant and crown index (PICI), complex esthetic index (CEI), and Copenhagen index score (CIS).<sup>[5-14]</sup>

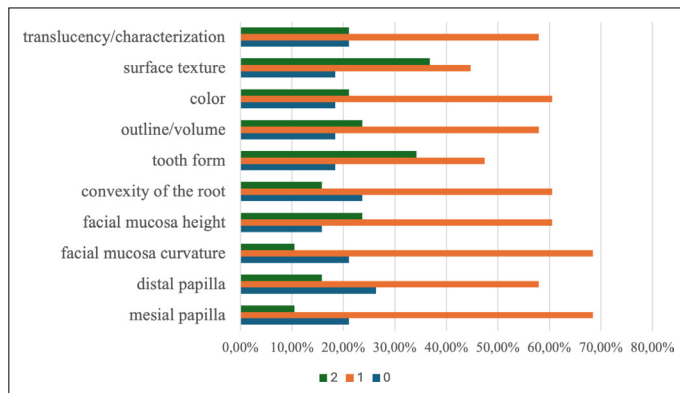
The papilla score was first developed to evaluate esthetics in implantology; this index is a scoring method that considers the vertical dimension of the papilla.<sup>[5]</sup> In 2005, Fürhauser et al.<sup>[7]</sup> introduced a new PES for the evaluation of peri-implant soft tissues. The introduced index is based on seven variables: mesial papilla, distal papilla, soft tissue level, soft tissue contour, alveolar crest, soft tissue color, and surface texture. Each variable was evaluated with a score of 2-1-0, with 2 being the best and 0 being the worst. All variables were evaluated in comparison with a reference tooth. Belser et al.<sup>[9]</sup> modified the previously published peri-implant soft tissue index "PES" and combined it with a new implant-supported restoration index "white esthetic score" (WES) developed for their study. The PES/WES score requires

soft and hard tissue assessment. The PES/WES assessment objectively evaluates the contour, volume, and surface texture of the crown in addition to root convexity and soft tissue assessment. The CIS evaluates six parameters: (i) crown morphology score, (ii) crown color matching score, (iii) symmetry/harmony score, (iv) mucosal discoloration score, (v) mesial papilla index score, and (vi) distal papilla index score. All esthetic parameters were categorized on a four-point scale. When scoring the parameters in the evaluation scale, Score 1 indicated excellent; Score 2, satisfactory; Score 3, moderate; and Score 4, poor.<sup>[12,14]</sup>

In the study conducted by comparing three different esthetic indices (PICI, ICEI, and PES/WES) for the evaluation of implant-supported single crowns, it was concluded that, compared with ICEI, PES/WES and PICI are more reproducible; therefore, PES/WES and PICI are more suitable as esthetic indices for single implant-supported crowns.<sup>[13]</sup> The aim of the present study was to evaluate implant-supported restorations in the anterior region using PES/WES and CIS and make an esthetic comparison with symmetrical natural teeth. The null hypothesis of the study is that there will be no difference between the PES/WES and CIS results.

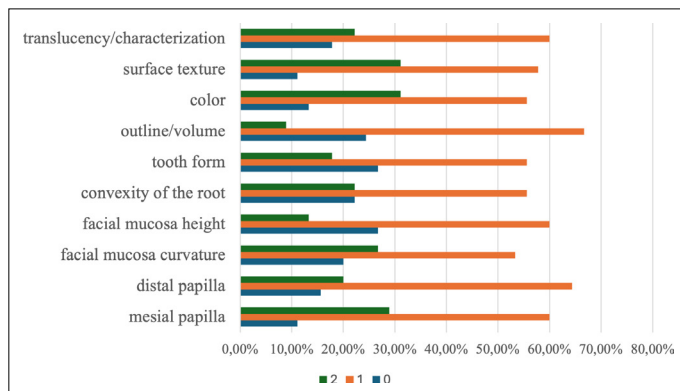
## Materials and Methods

This study was approved by the "Lokman Hekim University Scientific Research Ethics Board" (Türkiye) under protocol reference number 2024115 (28/03/2024). Artificial intelligence-supported technologies were not used during the study. Informed consent was obtained from each participant and the patients whose photographs would be shared before participation. Intraoral photographs of the patients were taken from the left lateral, right lateral, and anterior views under appropriate lighting conditions with a professional camera (Canon EOS 60D camera) and flash (Godox twin flash) suitable for dentistry (Fig. 1a-c). A total of forty-five 4<sup>th</sup> and 5<sup>th</sup> year dentistry students from Lokman Hekim University Faculty of Dentistry were asked to evaluate



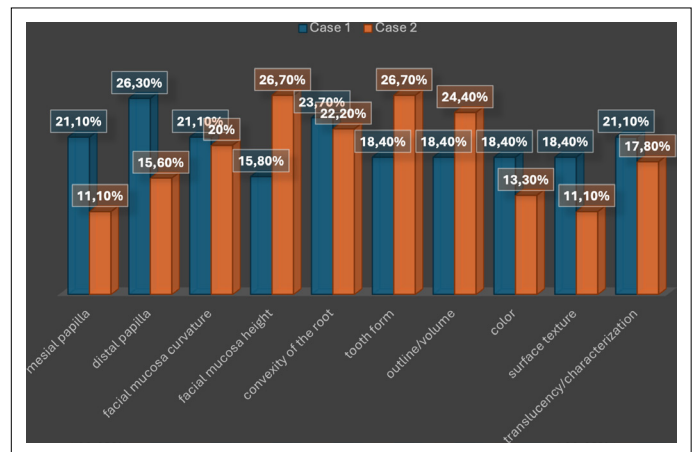
**Figure 2.** PES/WES Scores for Case 1.

PES: Pink esthetic score; WES: White esthetic score.



**Figure 3.** PES/WES Scores for Case 2.

two different patient photographs with a single implant in the anterior region (upper left canine and upper right lateral incisor) and symmetrical natural teeth on questionnaires using the PES, WES, and CIS. The questionnaire was designed in Turkish on a web-based Google form (Google LLC, Mountain View, California, United States of America), and the link was distributed to students via email, WhatsApp, and other social media platforms. All questions were answered anonymously, and informed consent was obtained from all participants by giving a summary of the study to the patients and subjects whose photographs would be used in the study. The questionnaire consisted of a total of 16 questions and included the PES, WES, and parameters used to evaluate the CIS. The parameters in the questionnaire to evaluate the PES or WES were as follows: mesial papilla, distal papilla, facial mucosa curvature, facial mucosa level, root convexity, soft tissue color, soft tissue surface structure, crown form, crown outline/volume, crown color, crown surface structure, crown translucency, and characterization. Each item was scored between 0 and 2 points, wherein 0 indicates a significant difference; 1, a slight difference; and 2, no difference. The CIS, which is another index to be used, consists of six parameters:



**Figure 4.** PES/WES "Score 0" for Cases 1 and 2.

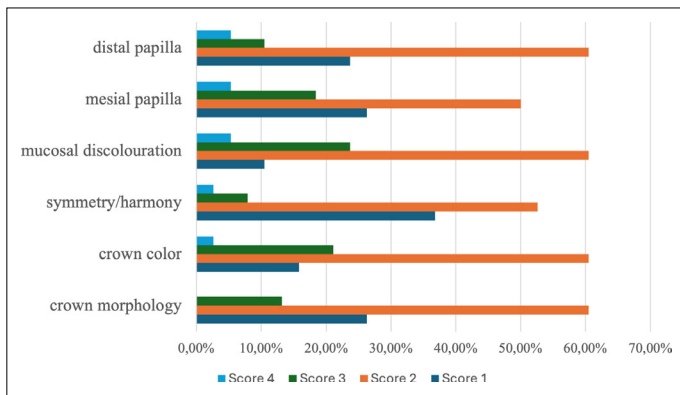
crown morphology score, crown color matching score, symmetry/harmony score, mucosal discoloration score, papilla index score at the mesial region, and papilla index score at the distal. For each question, there are four different evaluation options: Score 1, excellent; Score 2, satisfactory; Score 3, moderate; and Score 4, poor. The survey results were evaluated by comparing the percentages of the result data of the options marked on the Google form.

## Results

Forty percent of the 45 students who participated in the study were male and 60% were female. The scores obtained from evaluating the PES/WES outcomes for Cases 1 and 2 are displayed in Figures 2 and 3. For Case 1, the percentage of the mesial papilla that scored zero was 21.1%; the distal papilla 26.3%; the facial mucosa curvature 21.1%; the facial mucosa level 15.8%; the root convexity/soft tissue color/soft tissue surface structure 23.7%; the crown form 18.4%; crown outline volume 18.4%; crown color 18.4%; surface structure 18.4%; and crown translucency and characterization 21.1% (Fig. 2).

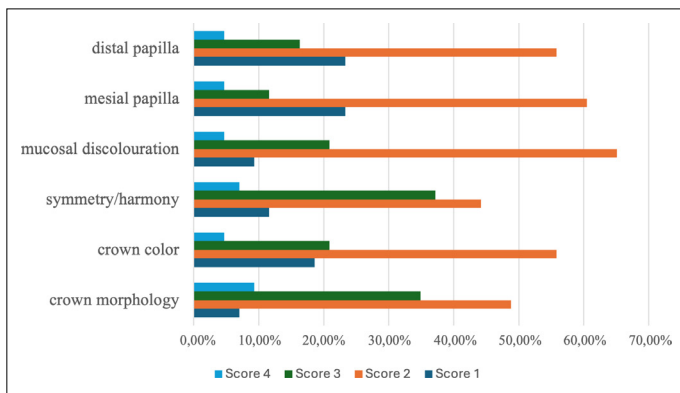
For Case 2, the following PES/WES score results were found for score 0: mesial papillae was 11.1%; distal papillae 15.6%; facial mucosa curvature 20%; facial mucosa level 26.7%; root convexity/soft tissue color/soft tissue surface structure 22.2%; crown form 26.7%; crown outline/volume 24.4%; crown color 13.3%; crown surface structure 11.1%; and crown translucency and characterization 17.8% (Fig. 3).

When Cases 1 and 2 were compared in terms of PES/WES scores, it was determined that the mesial, distal papillary, and facial mucosa curvature scores were more satisfactory in Case 2 than in Case 1. However, when the crown form and crown outline volume scores were evaluated, Case 1 had more satisfactory results (Fig. 4).



**Figure 5.** CIS for Case 1.

CIS: Copenhagen index score.

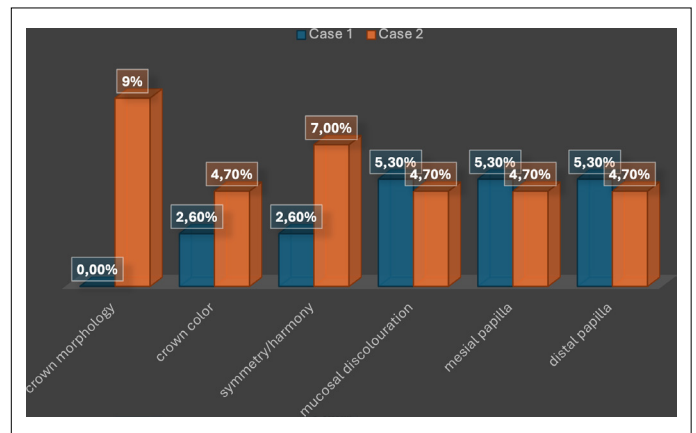


**Figure 6.** CIS for Case 2

The CISs for Cases 1 and 2 are displayed in Figures 5 and 6. Based on these results, the following scores were recorded for Case 1 for score 4: crown morphology 0%; crown color congruence 2.6%; symmetry/congruence 2.6%; mucosal discoloration 5.3%; mesial papilla 5.3%; and distal papilla 5.3% (Fig. 5). For Case 2, the scores were as follows for score 4: crown color matching 4.7%; crown shape 9.3%; symmetry/harmony 7%; mucosal discoloration 4.7%; mesial papilla 4.7%; and distal papilla 4.7% (Fig. 6). When Cases 1 and 2 were compared according to the CIS results, the crown morphology and symmetry/harmony scores of Case 1 were significantly more satisfactory than those of Case 2. However, the mesial and distal papilla results were similar in both cases (Fig. 7).

## Discussion

Measuring patients' satisfaction with treatment outcomes after dental treatments and evaluating factors affecting satisfaction are important for treatment success. However, scientific studies have shown no correlation between dental treatment quality and patient satisfaction.<sup>[15]</sup> This result demonstrated that patients concentrated on other visible and



**Figure 7.** CIS "Score 4" Points for Cases 1 and 2.

tactile metrics and were unable to accurately assess treatment quality. To ensure patient satisfaction, satisfactory esthetics and function should be provided. Numerous indices are used to evaluate the esthetics of implant-supported restorations. Despite the lack of universally accepted indices, the current clinical literature recommends PES and CEI for single-tooth implant-supported restorations.<sup>[15]</sup> A study by Cho et al.<sup>[16]</sup> compared the opinions of patients and expert observers about the esthetics of maxillary single dental implants in the esthetic region; it reported that the PES/WES index is a suitable tool for evaluating the esthetics of single implant-supported restorations and can provide objective results of esthetic scores in daily practice. It was also concluded that the index could be a useful tool in scientific research. For this reason, PES/WES was preferred in the present study.

One of the literature reviews showed that anterior single dental implants are a valid treatment option; however, they can lead to some difficulties with tooth color and permanent difficulties with the position of the implants and soft tissue contours. The review also reported that, from a clinician's perspective, PES/WES is still the most widely accepted method for evaluating the esthetic results of single implant-supported crowns in the maxillary anterior region.<sup>[17]</sup>

A study by Jones et al.<sup>[18]</sup> assessed single-tooth implant-supported restorations in the esthetic zone using PES and WES and involved three prosthodontists and 101 laypeople. Participants were asked to evaluate 27 photographs of single-tooth implants and non-implant restorations in the anterior region. According to the evaluation results obtained, laypeople more easily identified white than pink esthetic deficiencies. In the present study, since all the participants were dental students, no significant difference was observed when the PES/WES results were compared. Tettamanti et al.<sup>[13]</sup> compared three different esthetic indices for the evaluation of implant-supported single crowns.

A total of 10 prosthodontists (P), 10 orthodontists (O), 10 general dentists (G), and 10 laymen (L) independently evaluated 30 photographs and corresponding models with three different esthetic indices (PICI, ICEI, and PES/WES) and repeated the evaluations after 4 weeks. Based on the results obtained, it was concluded that, compared with the ICEI, the PES/WES and PICI were more reproducible; therefore, the PES/WES and PICI were more suitable as esthetic indices for single implant-supported crowns.

In 2022, Foong et al.<sup>[19]</sup> conducted a study aiming to evaluate and compare the esthetic results of anterior implant-supported single crowns with those of patients and clinicians. In total, 133 patients with 138 implant-supported restorations esthetic results were evaluated using a visual analog scale (VAS) questionnaire. Patients with crowns in the maxillary or mandibular canine region, a contralateral natural tooth, and a functional duration of at least 6 months were included in the study. Three trained prosthodontists evaluated each restoration using the PES/WES index from photographs and models. Two periodontists, two orthodontists, and two general practitioners each evaluated a random sample of 40 crowns using the same index for comparison. The prosthodontists had significantly lower mean PES, WES, and PES/WES scores than other specialties. At the end of the study, it was found that evaluator patients were less critical than clinicians, and there was a weak correlation between patients' subjective evaluation results and PES/WES index results evaluated by prosthodontists.

Hamdane et al.<sup>[12]</sup> evaluated the esthetics of implant-supported single crowns in the maxillary front region using four distinct indices. Both professional and lay groups participated, and the evaluation was repeated after 2–3 weeks. All indices evaluated in this study showed good intra- and inter-rater reproducibility; however, the validity of the esthetic indices evaluated using VAS (IREI and PICI) was higher than the validity of the indices using numerical ratings (PES, WES, and CIS). In a study using the CIS to test the reliability and validity of esthetic parameters used at the Copenhagen Dental School and compare professional and patient-reported esthetic results, Hosseini et al.<sup>[14]</sup> reported that the applicability, reliability, and validity of the CIS parameters and the esthetic use of implant-supported single-tooth restorations were beneficial. No significant correlation was found between professional- and patient-reported esthetic outcomes.

In the present questionnaire study, when the parameters of the PES for Case 1 were evaluated, except for the facial mucosa level, the participants marked the parameter indicating a significant difference with the symmetrical

tooth. In the same case, when the parameters of the WES were evaluated, a higher percentage of participants indicated no difference (score 2) than those who indicated a significant difference (score 0). When the PES/WES parameters for Case 1 are compared, participants' awareness of the parameters related to PES is more pronounced.

For Case 1, when the mesial and distal papilla indices in the CIS were compared with the papilla scores in the PES/WES index, the CIS gave more satisfactory results in the gingival evaluation. In the same case, when the crown color score in the PES/WES index was compared with the crown color matching in the CIS, it was observed that the PES/WES index gave higher esthetic results. Based on this, when evaluating the esthetic parameters of the case, scoring with more options is thought to indicate a more homogeneous distribution rather than a sharp transition between options or fewer options.

When analyzing the PES parameters for Case 2, the results were more consistent with the symmetrical tooth, except for the facial mucosa level. When analyzing the white esthetic parameters for the same patient, the patient was found to have acceptable esthetics compared with the symmetrical tooth, except for the form and the outline or volume of the crown. Comparing the PES/WES indices for this case, similar results were found in terms of awareness. In Case 2, when the papillary scores were evaluated with the indices, more satisfactory results were obtained in the CIS than in the PES/WES; crown color matching also showed better results in the CIS.

In this study, in which Cases 1 and 2 were compared with two different indices, the difference between the indices is attributed to the difference between the options that the indices offer to the participant during esthetic evaluation. The PES/WES index gives the participant the options of marked difference, slight difference, and no difference, whereas the CIS gives more options (perfect fit, satisfactory, moderate, and poor fit) that reduce the acuity of these options. Users have the opportunity to evaluate the four options to find the more accurate option for the case among the answers. Therefore, the null hypothesis that there will be no difference between the PES/WES and CIS results is rejected.

The limitations of the current study include the small number of clinical cases and participants evaluated, and the fact that the questionnaire was not repeated after a certain period of time.

Future studies with a larger number of participants from different specialties in dentistry and repeated use of a larger number of indices will provide more reliable results in terms of comparing indices.

## Conclusion

Within the limitations of this study, we conclude the following:

1. Given that the PES/WES index consists of three options, the slight difference value (score 1) was found to be higher. However, when the same cases were evaluated using the CIS, the satisfactory results (score 2) were found to be lower because this questionnaire has more options.
2. Using the esthetic index, which has more options like the CIS, may help achieve more accurate results.

**Ethics Committee Approval:** The Lokman Hekim University Scientific Research Ethics Committee granted approval for this study (date: 28.03.2024, number: 2024115).

**Authorship Contributions:** Concept: HGE; Design: HGE; Supervision: HGE; Fundings: CEK; Materials: CEK; Data Collection or Processing: CEK; Analysis or Interpretation: HGE; Literature Search: CEK; Writing: HGE, CEK; Critical Review: HGE.

**Conflict of Interest:** None declared.

**Use of AI for Writing Assistance:** Not declared.

**Financial Disclosure:** The authors declared that this study received no financial support.

**Peer-review:** Externally peer-reviewed.

## References

1. Ricciardi MT, Pizzi P. High-risk esthetically driven restoration: Begin with the end in mind. *Compend Contin Educ Dent* 2013;34(3):206–10.
2. Buser D, Martin W, Belser UC. Optimizing esthetics for implant restorations in the anterior maxilla: Anatomic and surgical considerations. *Int J Oral Maxillofac Implants* 2004;19 Suppl:43–61.
3. Bhuvaneshwaran M. Principles of smile design. *J Conserv Dent* 2010;13(4):225–32. [\[CrossRef\]](#)
4. Juodzbaly G, Wang HL. Esthetic index for anterior maxillary implant-supported restorations. *J Periodontol* 2010;81(1):34–42. [\[CrossRef\]](#)
5. Jemt T. Regeneration of gingival papillae after single-implant treatment. *Int J Periodontics Restorative Dent* 1997;17(4):326–33.
6. Hof M, Umar N, Budas N, Seemann R, Pommer B, Zechner W. Evaluation of implant esthetics using eight objective indices-Comparative analysis of reliability and validity. *Clin Oral Implants Res* 2018;29(7):697–706. [\[CrossRef\]](#)
7. Fürhauser R, Florescu D, Benesch T, Haas R, Mailath G, Watzek G. Evaluation of soft tissue around single-tooth implant crowns: The pink esthetic score. *Clin Oral Implants Res* 2005;16(6):639–44. [\[CrossRef\]](#)
8. Lai HC, Zhang ZY, Wang F, Zhuang LF, Liu X, Pu YP. Evaluation of soft-tissue alteration around implant-supported single-tooth restoration in the anterior maxilla: The pink esthetic score. *Clin Oral Implants Res* 2008;19(6):560–4. [\[CrossRef\]](#)
9. Belser UC, Grütter L, Vailati F, Bornstein MM, Weber HP, Buser D. Outcome evaluation of early placed maxillary anterior single-tooth implants using objective esthetic criteria: A cross-sectional, retrospective study in 45 patients with a 2- to 4-year follow-up using pink and white esthetic scores. *J Periodontol* 2009;80(1):140–51. [\[CrossRef\]](#)
10. Meijer HJ, Stellingsma K, Meijndert L, Raghoobar GM. A new index for rating aesthetics of implant-supported single crowns and adjacent soft tissues--the Implant Crown Aesthetic Index. *Clin Oral Implants Res* 2005;16(6):645–9. [\[CrossRef\]](#)
11. Li X, Wu B, Cheng X, Li Y, Xie X, Deng F. Esthetic evaluation of implant-supported single crowns: The implant restoration esthetic index and patient perception. *J Prosthodont* 2019;28(1):e51–8. [\[CrossRef\]](#)
12. Hamdane K, Nasri W. Esthetic evaluation of single implant-supported protheses: Comparative analysis of the reliability of the esthetic indices. *J Esthet Restor Dent* 2022;34(4):680–8. [\[CrossRef\]](#)
13. Tettamanti S, Millen C, Gavric J, Buser D, Belser UC, Brägger U, et al. Esthetic evaluation of implant crowns and peri-implant soft tissue in the anterior maxilla: Comparison and reproducibility of three different indices. *Clin Implant Dent Relat Res* 2016;18(3):517–26. [\[CrossRef\]](#)
14. Hosseini M, Gotfredsen K. A feasible, aesthetic quality evaluation of implant-supported single crowns: An analysis of validity and reliability. *Clin Oral Implants Res* 2012;23(4):453–8. [\[CrossRef\]](#)
15. Siegenthaler M, Strauss FJ, Gamper F, Hämmerle CHF, Jung RE, Thoma DS. Anterior implant restorations with a convex emergence profile increase the frequency of recession: 12-month results of a randomized controlled clinical trial. *J Clin Periodontol* 2022;49(11):1145–57. [\[CrossRef\]](#)
16. Cho HL, Lee JK, Um HS, Chang BS. Esthetic evaluation of maxillary single-tooth implants in the esthetic zone. *J Periodontal Implant Sci* 2010;40(4):188–93. [\[CrossRef\]](#)
17. Afrashtehfar KI, Assery MKA, Bryant SR. Aesthetic parameters and patient-perspective assessment tools for maxillary anterior single implants. *Int J Dent* 2021;2021:6684028. [\[CrossRef\]](#)
18. Jones AR, Martin W. Comparing pink and white esthetic scores to layperson perception in the single-tooth implant patient. *Int J Oral Maxillofac Implants* 2014;29(6):1348–53. [\[CrossRef\]](#)
19. Foong ALY, Tey VHS, Tan KBC, Teoh KH, Tan K. Esthetic evaluation of anterior implant-supported single crowns: A comparison between patients and dentists. *Int J Prosthodont* 2022;35(4):396–404. [\[CrossRef\]](#)